



New Onset Murmur and Hemodynamic Deterioration in a Patient with Infective Endocarditis

İnfektif Endokarditli Bir Hastada Hemodinamik Bozukluk ve Yeni Başlayan Üfürüm

İnfektif Endokarditli Hastada Yeni Başlayan Üfürüm / Onset Murmur in a Patient with Infective Endocarditis

Zekeriya Arslan¹, Murat Tavlaşoğlu², Leyla Guler³, Adem Guler², Mehmet Ali Şahin²,
¹Department of Cardiology, ²Department of Cardiovascular Surgery, Gülhane Military Medical Academy, Etlik,
³Anesteziyoloji A.D., Gazi Üniversitesi, Ankara, Turkey

Özet

İnfektif endokardit geniş spektrumlu antibiyotiklerin yaygın şekilde kullanılmasına rağmen paravalvüler abse ve aorta-kaviter fistül oluşmasına neden olabilir. Komplike infektif endokardit vakalarında uygulanan kompleks cerrahi girişimler, cerrahi tekniklerdeki gelişmelere paralel olarak daha kolay yapılabilir hale gelmesine rağmen mortalite hızları halen yüksektir. Biz bu yazımızda infektif endokardit ve bunun sonucunda hemodinamik bozukluğa neden olan aorta-kaviter fistül olgusunu sunduk. Olgumuzda aorta-kaviter fistül perikardiyal yama ile onarıldı ve aortik pozisyonda mekanik kapak replasmanı yapıldı. Postoperatif dönemde komplikasyon gelişmeyen hasta 28. günde antibiyotik tedavisinin tamamlanması sonrasında taburcu edildi. Tedavi şekli ve günümüzde uygulanan tedavi metodları literatür eşliğinde tartışıldı.

Anahtar Kelimeler

İnfektif Endokardit; Aorta-Kaviter Fistül; Üfürüm

Abstract

Despite the use of new wide spectrum antibiotics, infective endocarditis may lead to a paravalvular abscess or an aorta-cavitary fistula formation. Although the latest developments in surgical techniques give some advantages to perform an appropriate surgery in more complex operations in patients with complicated infective endocarditis, the mortality rates are still high. We hereby report a case of infective endocarditis caused a fatal complication that was aorta-cavitary fistula caused hemodynamic deterioration. The case underwent a successful surgical procedure in which fistula was repaired using a pericardial patch and mechanic valve prosthesis was implanted in aortic position. The case was discharged without any complication after finishing the antibiotic regime on the postoperative 28th day. We would like to discuss the treatment strategy of this case and current literature related management options will be presented.

Keywords

Infective Endocarditis; Aorta-Cavitary Fistula; Murmur

DOI: 10.4328/JCAM.783

Received: 22.08.2011 Accepted: 17.12.2011

Printed: 01.01.2015

J Clin Anal Med 2015;6(1): 91-3

Corresponding Author: Mehmet Ali Şahin, GATA Kalp Damar Cerrahisi A.D. 06010 Etlik, Ankara, Türkiye.

T.: +90 3123045243 F.: +90 3123045200 E-Mail: mali_irem@yahoo.com

Introduction

Infective endocarditis (IE) may cause some very serious complications. Paravalvular abscess formation that occurs due to local invasion of infection into the paravalvular tissue weakened and necrosed is one of these complications. Abscess and pseudoaneurysms involves and destructs surrounding tissue and sinuses of valsalva may occasionally be ruptured to the adjacent cardiac chambers causing an aorta-cavitary fistula (ACF). Periannular abscess and ACF incidence in patients with aortic valve IE is 22% and 2.2% respectively[1,2]. These aorta-cavitary communications may create an intra-cardiac shunt, which may result in further clinical deterioration and hemodynamic instability. Artificially during aortic valve surgery, chest trauma, aortic dissection and sinus valsalva aneurysm rupture are the known causes for ACF without IE.

Whatever the cause of ACF, surgical work is focused on two major tasks;

- 1- Determining the distinct clinical features, echocardiographical findings, management strategies for patients with ACF,
- 2- Determining the clinical impact of fistulous tract formation and outcomes of patients with infective aortic valve.

We hereby report a case that was surgically managed under the urgent hemodynamic conditions because of aorta-cavitary fistula occurred by aortic valve endocarditis.

Case Report

The patient was a 40 year old male with a history of acute rheumatic fever episode 35 years ago and he has been suffered from aortic valve disease for 17 years. He had been followed during this period without symptom but mild aortic stenosis (peak systolic gradient=10 to 20 mmHg) and mild aortic regurgitation (1st degree). He had weight loss, poor appetite and fatigue in the last three months. He complained at night sweats, fever and chills during one month, and had also dyspnea and orthopnea in ten days. He was markedly dyspneic and had heart failure findings (NYHA Class III). Blood tests, blood cultures and echocardiogram were performed, which were suggestive of infective endocarditis according to modified Duke criteria. Echocardiogram showed aortic valve disease with moderate aortic regurgitation, and abscess formation next to the non-coronary cusp, along with vegetations at the ventricular side of right coronary cusp of aortic valve and over the chordae of mitral anterior leaflet. Blood cultures grew viridians type Streptococci, therefore appropriate antibiotics were initiated according to sensitivity. Two days later, an audible diastolic heart murmur developed at the third intercostal level of left sternal border, with signs of decompensated congestive heart failure. Within hours, the patient hemodynamically deteriorated and referred for emergency surgery. During the operation, an oversized and oedematous heart with giant abscess was seen at the anterior part of ascending aorta. (Fig. 1) Cardiopulmonary by-pass was initiated using distal ascending aorta and right atrial single venous cannulation and myocardial protection was directly achieved by cold crystalloid cardioplegia. Vegetations at the base of right coronary cusp and over the mitral anterior leaflet were excised, and then the para-aortic abscess formation was visible between the aortic root and right ventricular outflow tract (Fig. 2). After large debridement of necrotic contents from the abscess cavity, a fistula

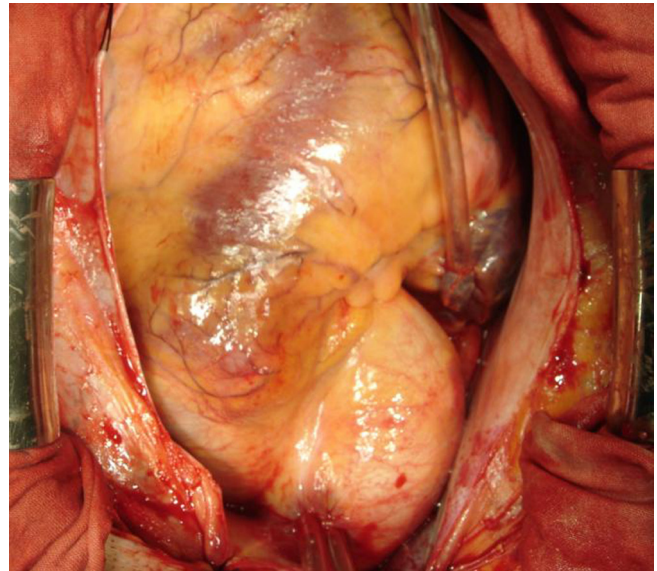


Figure 1. An oversized and oedematous heart with giant abscess was seen at the anterior part of ascending aorta.

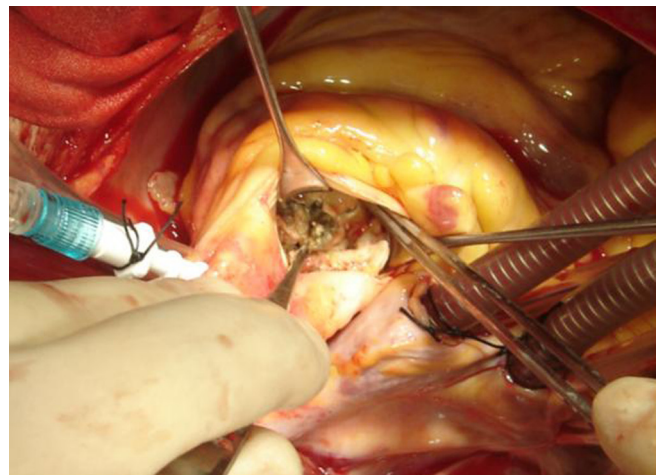


Figure 2. Para-aortic abscess formation between the aortic root and right ventricular outflow tract was shown.

between non-coronary sinus of valsalva and right ventricular outflow tract was noticed. The fistula was closed with a pericardial patch sutured by interrupted pledgeted Prolene® (Ethicon Inc. Somerville NJ). Then intermittent, pledgeted sutures for valve replacement were passed through all of the aortic annulus except the non-coronary sinus of valsalva, where the sutures were taken from outside to inside the aortic wall for a stronger bite. Then St Jude® (St. Paul, MN) mechanical bileaflet heart valve was implanted to aortic position. After the discontinuation of cardiopulmonary by-pass, transesophageal echocardiography (TEE) showed no residual shunt within aorta-cavitary fistula and normal functioning of prosthetic aortic valve. The patient required inotropic support during the early postoperative period but the rest of the postoperative course was uneventful and the patient was discharged on the postoperative 18th day. Cultures of debrided material also grew viridans type Streptococci and the initial antibiotherapy was continued for 6 weeks.

Discussion

ACFs in the setting of IE may be diagnosed by using preoperative echocardiography, inspection during surgery, or post-mortem examination. Echocardiographically; abscesses are defined

as abnormal echo-dense or echo-lucent areas within the valvular annulus or paravalvular tissue in more than one echocardiographic plane in the setting of valvular infection, and ACF is defined as abnormal communication between aorta and cardiac chambers with turbulent systolic and diastolic flow assessed by continuous or colour doppler mapping. TEE is superior to transthoracic echocardiography (TTE) in detecting the fistulous tracts in 97% of cases, whereas TTE might detect only 53%[1]. For this reason, TEE might play a critical role in detecting early abscess formation, enabling close monitoring before the onset of clinical deterioration.

A study [1] found the median duration of symptoms to diagnosis of IE as 19 days and median duration of symptoms to echocardiographic detection of fistulization as 25 days. They also reported the clinical or radiological signs of heart failure to be present in 62% of patients, which was more common in native valve endocarditis than prosthetic valve endocarditis (PVE). But the mortality rate of heart failure in the setting of PVE might be as high as 40%. Our patient's constitutional symptoms had been for 3 months, signs of heart failure had been for 10 days and hemodynamic deterioration began a few hours before the operation.

Another study [2] concluded that in abscesses larger than 10mm, (more than 3/4 of patients with paravalvular abscesses) the risk of fistula formation was higher, and the site of origin of the fistulous tracts was equally distributed among the three sinuses of valsalva. Similarly, the four cardiac chambers were also equally involved in the fistulous tracts. According to their results, the most common sites of fistulous tracts were the right coronary sinus to the right ventricle, secondly the non-coronary sinus to the right ventricle, and finally the left coronary sinus to the left atrium. Hemodynamic effects of fistulas depend on left-to-right or left-to-left shunts volume amount, localization of the rupture, and the size of the defect. In our case, a communication between non-coronary aortic sinus and right ventricular outflow tract was present, and the mechanism of sudden hemodynamic deterioration was due to right ventricular overload.

In a pathophysiologic view, peri-annular abscesses with fistulas represent a further step in aortic annular erosion, causing extension of infection beyond the leaflets and aortic annular ring. However, in some cases, IE may directly dissect the aortic wall and create a pseudo-aneurysm or a fistula without previous formation of an abscess. An existing IE on a prosthetic valve is more frequently complicated by abscess formation, because infection begins as periannulitis and extends to the annular connective tissue resulting in loosening of the sutures and development of paravalvular leak and ultimately abscess cavity occurring.

Staphylococcal and Streptococcal pathogens were found to be the most common causes in patients with abscess formation, accounting for 64% of cases. Staphylococci were also the most common microorganisms responsible for 46% of ACF, while Streptococci were identified in 33% of patients [2]. In our patient, viridans group Streptococci was the etiologic agent. Literature data address radical debridement, curetting the slimy endothelial surface of aortic root, and local disinfection as the only way to eliminate the biofilm bacteria (bacteria which can colonize easily inside tissues) from the infected tissue or

to decolonize the biofilm, in order to minimize the incidence of residual or recurrent endocarditis which might occur despite effective antibiotherapy[3].

ACF might be closed using different techniques, which are chosen according to the degree of anatomical disruption (simple closure, pericardial, or Gore-Tex® patches). We preferred closing the fistula with the fresh pericardial patch, which is more resistance material for infection. In a study with 76 patients with IE and subsequent ACF undergoing repair; 48% were repaired by using pericardial patch, 41% with simple sutures, and 11% by using gore-tex patch [1]. In the same group, concomitant valve replacement was performed with mechanical valve in 50%, bioprosthesis in 24%, and cryopreserved homograft in 18% [1]. Homograft valve replacement is the procedure of choice in patients with aortic root IE. But due to shortage in the availability of homografts in some centers, mechanical or bioprosthetic valves might also be used. While using a mechanical valve, preventing any contact of the prosthetic valve with the abscess cavity is of utmost importance. Therefore the use of a pericardial patch helps to be created a new shelf to differ from evacuated cavity and prosthesis as well.

The mortality and morbidity rate of ACF is high, because over 60% of patients with ACF develop significant heart failure, and over 40% of them die. Moderate or severe heart failure is a significant independent risk factor for death. Patients with ACF are more likely to develop third-degree heart block as well (11%). Despite all efforts, surgical treatment did not decrease the mortality rate. The actuarial 5-year survival rate in surgical survivors was 80% in patients with fistulae, and 92% in patients with nonruptured abscesses [4].

In conclusion; if an ACF occurring with IE on aortic position leads serious hemodynamic deterioration that is uncontrollable to pharmacologic support, urgent surgical treatment should be chosen. Pericardial patch and metallic prosthetic valve can be safely used after evacuating abscess material and cavity.

Competing interests

The authors declare that they have no competing interests.

References

1. Anguera I, Miro JM, Vilacosta I, Almirante B, Anguita M, Munoz P, et al. Aortocavitary fistulous tract formation in infective endocarditis: clinical and echocardiographic features of 76 cases and risk factors for mortality. *European Heart Journal* 2005;26(3):288-97.
2. Anguera I, Miro JM, Cabell CH, Abrutyn E, Fowler VG, Hoen B, et al. Clinical characteristic and outcome of endocarditis with periannular abscess in the international collaboration on endocarditis merged database. *Am J Cardiol* 2005;96(7):976-81.
3. Yankah AC, Pasic M, Klose H, Siniawski H, Weng Y, Hetzer R. Homograft reconstruction of the aortic root for endocarditis with periannular abscess: a 17 year study. *Eur J Cardiothoracic Surg* 2005;28(1):69-75.
4. Anguera I, Miro JM, Evangelista A, Cabell CH, Roman JAS, Vilacosta I, et al. Periannular complications in infective endocarditis involving native aortic valves. *Am J Cardiol* 2006;98(9):1254-60.